



Research Article

ISSN: 0975-248X  
CODEN (USA): IJPSPP

## **Ginger and Marshmallow Extracts Can Protect against Pyloric Ligation-Induced Peptic Ulcer in Rats**

**Sameh S. Zaghlool<sup>1\*</sup>, Basim A. Shehata<sup>2</sup>, Ali A. Abo-Seif<sup>1</sup>, Hekma A. Abd El-Latif<sup>3</sup>**

<sup>1</sup>Pharmacology and Toxicology Department, Faculty of Pharmacy, Nahda University, Egypt

<sup>2</sup>Pharmacology and Toxicology Department, Faculty of Pharmacy, Beni-Suef University, Egypt

<sup>3</sup>Pharmacology and Toxicology Department, Faculty of Pharmacy, Umm Al-Qura University, KSA

### **ABSTRACT**

Gastric ulcer is one of the most serious diseases over wide the world. There are many drugs used for the treatment of gastric ulcer, but most of these produce several adverse reactions. This study aims to investigate the protective effects of extracts of Ginger and Marshmallow on pyloric ligation-induced gastric ulcer in rats. Animals were divided into 5 Groups; a normal control group, an ulcer control group, a standard treatment group receiving famotidine (20 mg/kg), and two treatment groups receiving Ginger (100 mg/kg) and Marshmallow (100 mg/kg). Treatments were given orally for 14 days. On the 15th day, animals were subjected to pyloric ligation except for the normal control group. Four hours later, rat stomachs were excised and gastric juice and blood samples were collected. Pyloric ligation caused significant elevations in ulcer number, ulcer index, gastric volume, titratable acidity, acid output, mucin content and peptic activity, accompanied by significant decreases in blood superoxide dismutase activity (SOD) activity and gastric mucosal nitric oxide (NO) and glutathione (GSH) contents. In addition, elevations in gastric mucosal lipid peroxide and histamine contents were observed. Pretreatment with famotidine, ginger or marshmallow significantly corrected all blood and tissue parameters by varying degrees. Famotidine, ginger and marshmallow may protect against pyloric ligation-induced peptic ulcer in rats, being promising for further clinical trials.

**Keywords:** Famotidine, Ginger, Marshmallow, Peptic ulcer, Pyloric ligation, Pretreatment.

### **INTRODUCTION**

Peptic ulcer is one of the world's major gastro-intestinal disorders, embracing both gastric and duodenal ulcers, and affecting 10% of the world population. [1] The pathogenesis of peptic ulcer disease includes a complex imbalance between gastric offensive factors like increased gastric acid and pepsin secretion, *Helicobacter pylori* (*H. pylori*) infection, bile salts, ethanol,

medications like NSAIDs, and lipid peroxidation, and defensive mucosal factors like prostaglandins (PG's), gastric mucus, cellular renovation, blood flow, mucosal secretion, proliferation and antioxidant defense mechanisms like catalase (CAT), superoxide dismutase (SOD), nitric oxide (NO) and glutathione (GSH). [1]

Famotidine is an H<sub>2</sub> receptor antagonist that inhibits acid production by reversibly competing with histamine for binding with H<sub>2</sub> receptors located at the basolateral membrane of the parietal cells. [2-3] Histamine H<sub>2</sub> receptor antagonists not only inhibit acid secretion induced by histamine, gastrin and cholinergic stimulation, but can also promotes healing of ulcers. [4-5]

**\*Corresponding author: Dr. Sameh S. Zaghlool,**  
Faculty of Pharmacy, Nahda University, Beni Suef,  
Egypt; **Tel.:** 002-01005113065;

**E-mail:** samehsaadzaghloul@yahoo.com

**Received:** 10 March, 2015; **Accepted:** 13 March, 2015

The use of phytoconstituents as drug therapy to treat major ailments has proved to be clinically effective and relatively less toxic than traditional drugs, based on their ability to reduce offensive factors, particularly oxidative stress.<sup>[6]</sup>

Ginger (*Zingiber officinale* Roscoe, family: Zingiberaceae) is a herbal drug reported to stimulate digestion and absorption<sup>[13]</sup> and to relieve constipation and flatulence by increasing muscular activity in the digestive tract.<sup>[7-9]</sup>

In folk medicine and literatures, Marshmallow (*Althaea officinalis* L., family: Malvaceae) was used in gastrointestinal disorders.<sup>[10]</sup> Aqueous Marshmallow flower extract demonstrated a protection against ethanol-induced gastric ulcer. It has been shown that mucilage and flavonoids have the property of covering and protecting gastric mucosa, thereby reducing the incidence of gastric ulcer.<sup>[11-12]</sup>

Based on the aforementioned data, the aim of the present study is to determine protective effects of ginger and marshmallow extracts on pyloric ligation-induced peptic ulcer in rats.

## MATERIALS AND METHODS

### Animals

Adult male albino rats weighing 200-250 g were used in the present investigation. Animals were obtained from the animal house of Nahda University, Beni-Suef and were kept under observation for about 15 days before the onset of the experiment to exclude any inter-current infection. The chosen animals were housed in plastic cages with good aerated covers at 25±0.5°C under 12 hour's light/dark periods. Animals were allowed free access of water and were supplied daily with standard forage *ad libitum*. All animal housing and handling were conducted in compliance with the Beni-Suef University guidelines and in accordance with the research protocols established by the Animal Care Committee of the National Research Center (Cairo, Egypt) which followed the recommendations of the National Institutes of Health Guide for Care and Use of Laboratory Animals (Publication No. 85-23, revised 1985).

### Plant materials and Preparation of extract

Ginger and marshmallow were purchased from Haraz Company, Cairo, Egypt and were identified phytochemically<sup>[14-15]</sup> by staff members of the Department of Pharmacognosy, Faculty of Pharmacy, Nahda University.

Aqueous extract of marshmallow was prepared by soaking the dried flowers of Marshmallow (1 kg) in hot water (85-90°C) for half an hour, followed by filtration and drying of the filtrate under reduced pressure<sup>[12]</sup>, with a final yield of about 11.8%. The residue was dissolved in normal saline in a concentration of 100 mg/mL, and kept for oral administration.

Alcoholic extract of ginger was prepared by cutting rhizomes into small pieces that were completely dried in shed up for 3-4 days. Powder (1 kg) was obtained

with the help of a mixer, and then extraction was done using 50% ethanol (v/v). The homogenate was concentrated on rotavapour (IKA® RV 10, Digital, 20-270 rpm - IKA® HB 10, Basic, 0-180°C made in Germany). The residue was designated as ethanol extract (11.5 g). The extract was pre-solubilized in distilled water for the *in vivo* studies.<sup>[13]</sup> The residue was dissolved in normal saline, 100 mg/mL, and prepared for oral use.

### Drugs, chemicals and reagent kits

All chemicals used in the study were of analytical grade. Famotidine was obtained as a gift from Amoun Pharmaceutical Industries Company "APIC", Cairo, Egypt. Histamine reagent kit was obtained from Oxford Biomedical Research, Inc., USA. Malondialdehyde (MDA) reagent kit was obtained from Cell Biolabs, Inc., USA. NO reagent kit was obtained from Assay Designs, Inc., USA. GSH reagent kit was obtained from Cell Biolabs, Inc., USA. SOD reagent kit was obtained from Cell Biolabs, Inc., USA.

### Experimental Design

Rats were randomly allocated into 5 groups, each consisting of 6-8 rats, where test drugs or vehicles were administered by oral feeding tube once daily for 14 days prior to induction of ulcer. Group I: received 10 ml/kg normal saline, *p.o.* and served as normal control group, Group II: received 10 ml/kg normal saline, *p.o.* and served as peptic ulcer control group, Group III: received Famotidine (20 mg/kg/day, *p.o.*)<sup>[16-17]</sup> and served as standard treatment group, Group IV: received Ginger (100 mg/kg/day, *p.o.*)<sup>[13, 18]</sup>, and Group V: received Marshmallow (100 mg/kg/day, *p.o.*)<sup>[12]</sup>

### Induction of peptic ulcer and sample preparation

On 15<sup>th</sup> day of drug or vehicle administration, animals were anaesthetized with urethane (1.25 g/kg, *i.p.*), carefully dissected and subjected to pyloric ligation<sup>[19]</sup> except for the normal control group, after 36 hours of starvation. Four hours after pyloric ligation, animals were sacrificed by cervical dislocation under anesthesia. Stomachs were isolated and the gastric juice was collected and its volume was measured. Blood samples were collected from the retino-orbital sinus. The glandular portion of the stomach was then exposed and examined for macroscopic examination and ulcer index determination. Total acid output was estimated and gastric mucosal homogenates were prepared in normal saline.

### Assessment of Gross Mucosal Damage

The gastric mucosal layer was carefully inspected for the occurrence of ulcers and their numbers were counted with the aid of an illuminated magnifying lens (10x).<sup>[20-21]</sup> The sum of the total length of long ulcers and hemorrhagic spots in each group of rats were divided by the number of animals to calculate the ulcer index (mm). Ulcer index was calculated according to the method described by Cho and Olge (1979).<sup>[22]</sup> The preventive index was calculated according to the method described by Hano *et al.* (1976).<sup>[23]</sup>

$$\text{Preventive Index (\%)} = \frac{\text{Ulcer Index (Ulcer Control group)} - \text{Ulcer Index (Treated group)}}{\text{Ulcer Index (Ulcer Control group)}} \times 100$$

### Gastric Volume, Titratable Acidity, and Acid Output Determination

The collected gastric juice was centrifuged at 3000 g for 10 min and gastric volume (mL) was recorded after removal of solid debris. Samples having solid mass volumes more than 0.6 mL was discarded. [19] Titratable acidity was carried out according to the method of Shay *et al.*, (1954) [24] and Grossman (1963) [25] by titrating gastric juice against sodium hydroxide (0.01 N) using phenol red as an indicator. Acid output was calculated as the rate of the gastric juice production [26] as microequivalents per 4 hours.

$$\text{Acid Output (\mu Eq/4hr)} = \frac{T \times V}{4}$$

Where: (T) is titratable acidity (mEq/l) and (V) is collected volume of gastric juice (ml).

### Peptic Activity Determination

Briefly, pepsin activity, the active principle proteolytic activity of gastric secretion was determined in terms of the amount of proteases produced after incubation of the substrate with pepsin for half an hour. The proteolytic activity of pepsin in gastric juice was determined spectrophotometrically at 280 nm. [27]

### Mucin Content Determination

The mucin content of the gastric juice was determined. [28] Briefly, to diluted samples orcinol (1.6%) and sulphuric acid (60%) were added, vortexed and boiled for 10 min. Mixtures were cooled in ice-cold water to stop the reaction and the absorbance was measured spectrophotometrically at 425 nm.

### Determination of gastric mucosal histamine

Histamine content of the gastric mucosa was determined using Enzyme Immunoassay for Histamine at 650 nm. [29-30]

### Determination of gastric mucosal reduced glutathione (GSH)

The level of GSH was determined in stomach homogenate spectrophotometrically at 405 nm. [31-32]

### Determination of gastric mucosal lipid peroxides (MDA)

Lipid peroxides formation was determined in gastric mucosal homogenate spectrophotometrically at 532 nm. [33-34]

### Determination of gastric mucosal nitric oxide (NO)

Total NO concentration was determined in gastric mucosal homogenate spectrophotometrically at 540 ± 20 nm. [35]

### Determination of blood superoxide dismutase (SOD)

SOD activity was determined in blood spectrophotometrically at 490 nm. [36-37]

### Histopathological examination of stomach

Hematoxylin and Eosin (H & E) was used for histological examination of the general structure of the stomach. [38] The effect of drugs was evaluated through assessment of the inflammatory and necrotic changes in the mucosal tissue.

## Statistical analysis

Statistical analysis and the significance of difference between groups mean was determined using one-way ANOVA test followed by Tukey-Kramer multiple comparisons test, using *GraphPad Instat* computer software, San Diego, USA. Graphs and tables were performed using *Microsoft Excel 2010* computer program.

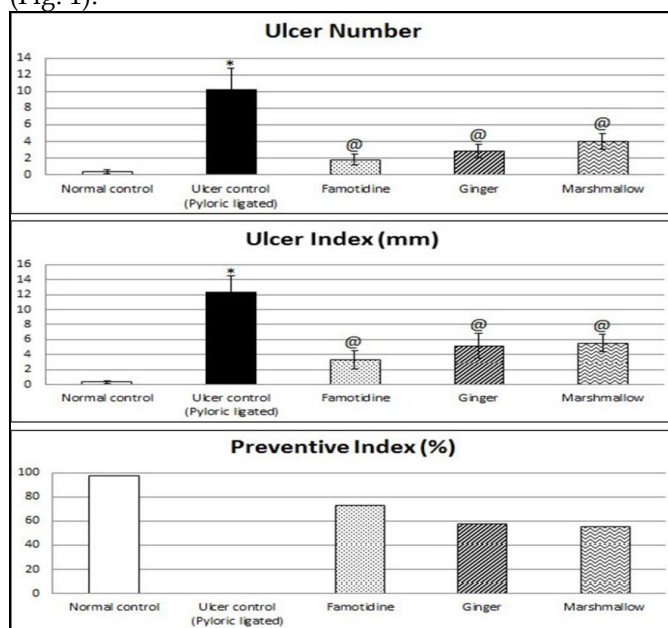
## RESULTS

### Preliminary phytochemical screening of extracts

The phytochemical screening of alcoholic extract of Ginger revealed the presence of carbohydrates, volatile oils, sterols, triterpenoids and alkaloids. The phytochemical screening of aqueous extract of Marshmallow revealed the presence of carbohydrates, volatile oils, tannins, flavonoids, and traces of saponins.

### Macroscopic examination (Ulcer number, ulcer index and preventive index)

Rats subjected to pyloric ligation (ulcer control rats) showed significant ulceration in the glandular area of their stomachs compared to normal control rats. Pretreatment with famotidine significantly reduced ulcer number and ulcer index to about 18.01% and 27%, respectively, as compared to ulcer control group. Similarly, ginger pretreatment significantly reduced ulcer number and ulcer index to about 27.85% and 41.45%, respectively. In addition, marshmallow pretreatment significantly reduced ulcer number and ulcer index to about 39.37% and 44.6%, respectively (Fig. 1).

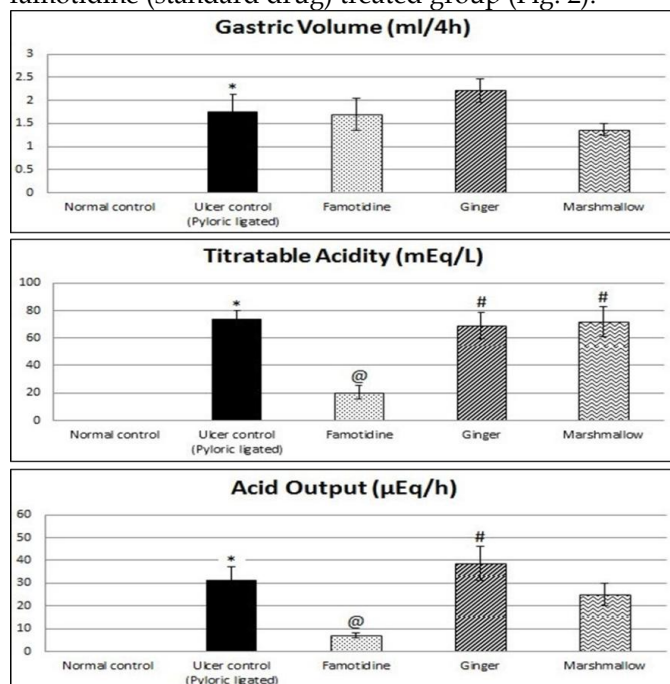


**Fig. 1: Protective effects of 14 days daily treatment with Famotidine, Ginger and Marshmallow on Ulcer number, Ulcer Index and Preventive Index in Pyloric Ligation-induced gastric ulceration in rats.**

Each value represents the mean of 6-8 animals ± standard error of the mean. Statistical analysis was determined using one - way ANOVA test followed by Tukey-Kramer multiple comparisons test. \*Significantly different from normal control group ( $p < 0.05$ ). @Significantly different from ulcer control group ( $p < 0.05$ ). #Significantly different from famotidine (standard drug) treated group ( $p < 0.05$ ).

**Gastric volume, titratable acidity and acid output**

Rats subjected to pyloric ligation showed significant elevation in gastric volume, titratable acidity and acid output, reaching values of  $1.75 \pm 0.37$  ml/4h,  $73.688 \pm 6.26$  mEq/L and  $31.2 \pm 5.86$   $\mu$ Eq/4h, respectively. Pretreatment with famotidine did not significantly change gastric volume but significantly decreased titratable acidity and acid output to 27.37% and 23.14%, respectively as compared to ulcer control group. Similarly ginger pretreatment did not significantly affect gastric volume, titratable acidity or acid output as compared to ulcer control group, but significantly increased titratable acidity and acid output to 340.83% and 537.25%, respectively, as compared to famotidine (standard drug) treated group. In addition, marshmallow pretreatment did not significantly affect gastric volume, titratable acidity or acid output as compared to ulcer control group but it significantly increased titratable acidity to 357.15% compared to famotidine (standard drug) treated group (Fig. 2).

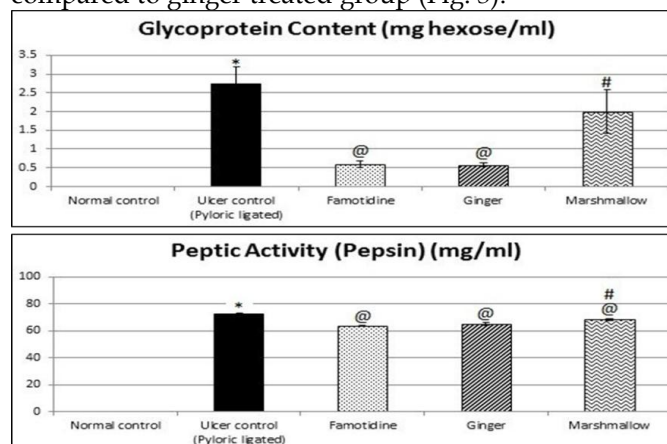


**Fig. 2: Protective effects of 14 days daily treatment with Famotidine, Ginger and Marshmallow on Gastric volume, Titratable acidity and Acid output in Pyloric Ligation-induced gastric ulceration in rats.** Each value represents the mean of 6–8 animals  $\pm$  standard error of the mean. Statistical analysis was determined using one - way ANOVA test followed by Tukey-Kramer multiple comparisons test. \*Significantly different from normal control group ( $p < 0.05$ ). @Significantly different from ulcer control group ( $p < 0.05$ ). #Significantly different from famotidine (standard drug) treated group ( $p < 0.05$ ).

**Results of gastric acid secretion (Peptic activity and mucin concentration)**

Rats subjected to pyloric ligation (ulcer control rats) showed increase in glycoprotein content and peptic activity as it was  $2.74 \pm 0.45$  mg hexose/ml and  $72.73 \pm 0.635$  mg/ml, respectively. Pretreatment with famotidine significantly decreased glycoprotein content and peptic activity to 21.53% and 87.47%, respectively as compared to ulcer control group. Similarly, ginger pretreatment significantly decreased glycoprotein

content and peptic activity to 21.13% and 89.54%, respectively. In addition, marshmallow pretreatment did not significantly affect glycoprotein content but it significantly decreased peptic activity to 93.8%. It also significantly increased glycoprotein content and peptic Activity to 337.28% and 107.23%, respectively as compared to famotidine (standard drug) treated group. Also it significantly increased glycoprotein content and peptic activity to 343.69% and 104.76%, respectively as compared to ginger treated group (Fig. 3).

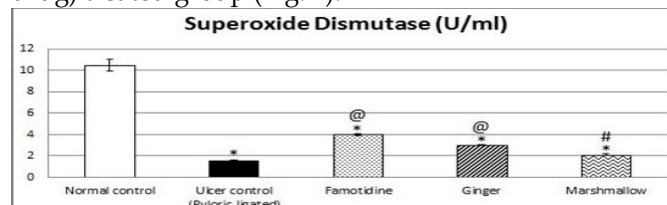


**Fig. 3: Protective effects of 14 days daily treatment with Famotidine, Ginger and Marshmallow on Glycoprotein Content and Peptic Activity in Pyloric Ligation-induced gastric ulceration in rats.**

Each value represents the mean of 6–8 animals  $\pm$  standard error of the mean. Statistical analysis was determined using one - way ANOVA test followed by Tukey-Kramer multiple comparisons test. \*Significantly different from normal control group ( $p < 0.05$ ). @Significantly different from ulcer control group ( $p < 0.05$ ). #Significantly different from famotidine (standard drug) treated group ( $p < 0.05$ ).

**Results of on blood samples collected (Superoxide Dismutase Activity)**

Rats subjected to pyloric ligation (ulcer control rats) showed significant decrease in SOD activity to 14.57% as compared to normal control rats. Pretreatment with famotidine significantly increased SOD activity to 262.95% as compared to ulcer control group. Ginger pretreatment significantly increased SOD activity to 198.69%. In addition, marshmallow pretreatment did not significantly affect SOD activity as compared to ulcer control group but significantly decreased SOD activity to 52.12% as compared to famotidine (standard drug) treated group (Fig. 4).



**Fig. 4: Protective effects of 14 days daily treatment with Famotidine, Ginger and Marshmallow on Superoxide Dismutase in Pyloric Ligation-induced gastric ulceration in rats.**

Each value represents the mean of 6–8 animals  $\pm$  standard error of the mean. Statistical analysis was determined using one - way ANOVA test followed by Tukey-Kramer multiple comparisons test. \*Significantly different from normal control group ( $p < 0.05$ ). @Significantly different from ulcer control group ( $p < 0.05$ ). #Significantly different from famotidine (standard drug) treated group ( $p < 0.05$ ).



**Table I: Protective effects of 14 days daily treatment with Famotidine, Ginger and Marshmallow on Nitric Oxide, Glutathione, Malondialdehyde and Histamine in Pyloric Ligation-induced gastric ulceration in rats.**

Group	Treatment	Glutathione		Nitric Oxide		Malondialdehyde		Histamine	
		$\mu\text{mol/g}$ tissue	% of control ulcer	$\mu\text{mol/g}$ tissue	% of control ulcer	$\text{nmol/g}$ tissue	% of control ulcer	$\text{ng/g}$ tissue	% of control ulcer
Group 1	Normal control	$5.67 \pm 0.28$	644.32	$182.77 \pm 9.29$	561.5	$18.67 \pm 0.83$	15.26	$1.79 \pm 0.06$	14.49
Group 2	Ulcer control (Pyloric ligated)	$0.88 \pm 0.04^*$	100	$32.55 \pm 2.52^*$	100	$122.37 \pm 3.75^*$	100	$12.35 \pm 0.46^*$	100
Group 3	Famotidine (20 mg/kg, p.o.)	$2.55 \pm 0.22^{*\oplus}$	289.77	$126.15 \pm 3.07^{*\oplus}$	387.56	$33.92 \pm 1.87^{*\oplus}$	27.72	$3.34 \pm 0.17^{*\oplus}$	27.04
Group 4	Ginger (100 mg/kg, p.o.)	$2.06 \pm 0.03^{*\oplus}$	234.1	$97.3 \pm 3.83^{*\oplus\#}$	298.92	$46.6 \pm 2.25^{*\oplus\#}$	38.08	$4.55 \pm 0.23^{*\oplus}$	36.84
Group 5	Marshmallow (100 mg/kg, p.o.)	$1.09 \pm 0.02^{*\#}$	123.86	$49.7 \pm 1.72^{*\#}$	152.69	$93.85 \pm 4.4^{*\oplus\#}$	76.69	$9.35 \pm 0.4^{*\oplus\#}$	75.71

Each value represents the mean of 6-8 animals  $\pm$  standard error of the mean. Statistical analysis was determined using one - way ANOVA test followed by Tukey-Kramer multiple comparisons test. \*Significantly different from normal control group ( $p < 0.05$ ).  $\oplus$ Significantly different from ulcer control group ( $p < 0.05$ ).  $\#$ Significantly different from famotidine (standard drug) treated group ( $p < 0.05$ ).

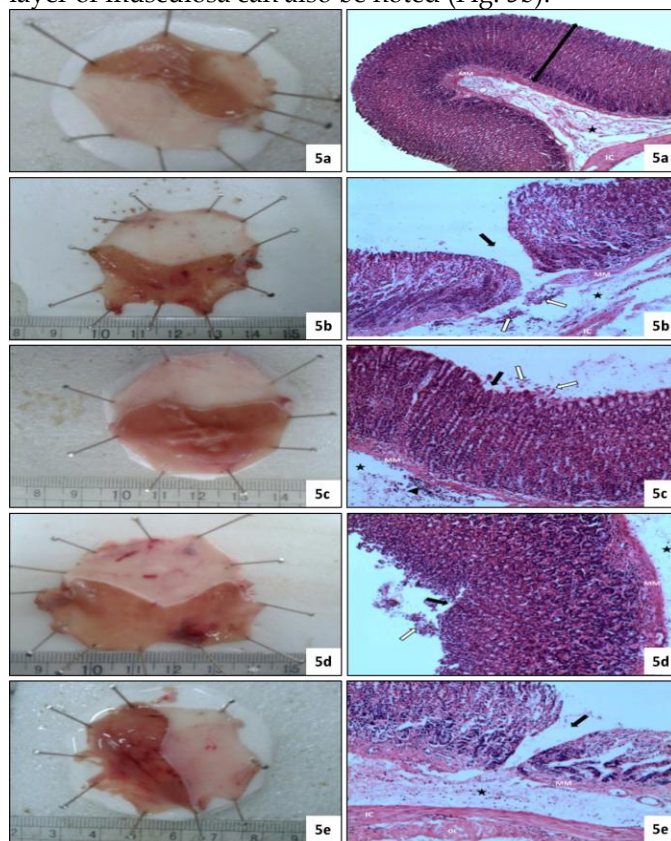
### Results of gastric mucosal tissues (Nitric oxide, Glutathione, Malondialdehyde and Histamine Content)

Rats subjected to pyloric ligation (ulcer control rats) showed significant decrease in GSH and NO content to 15.52% and 17.81%, respectively and significantly increased MDA and histamine content to 655.43% and 689.94%, respectively as compared to normal control rats. Pretreatment with famotidine significantly increased GSH and NO content to 289.77% and 387.56%, respectively and significantly decreased MDA and histamine content to 27.72% and 27.04%, respectively as compared to ulcer control group. Ginger pretreatment significantly increased GSH content and NO content to 234.1% and 298.92%, respectively as compared to ulcer control group and significantly decrease NO content to 77.13% compared to famotidine (standard drug) treated group. It significantly decreased MDA and histamine content to 38.08% and 36.84%, respectively as compared to ulcer control group and significantly increased MDA content to 137.38% compared to famotidine (standard drug) treated group. In addition, marshmallow pretreatment did not significantly affect GSH or NO content compared to ulcer control group but it significantly decreased GSH and NO content to 42.74% and 39.39%, respectively as compared to famotidine (standard drug) treated group and it significantly decreased GSH and NO content to 52.91% and 51.07%, respectively as compared to ginger treated group respectively. Marshmallow also significantly decreased MDA and histamine content to 76.69% and 75.71%, respectively as compared to ulcer control group. It significantly increased MDA and histamine content to 276.68% and 279.94%, respectively as compared to famotidine (standard drug) treated group and significantly increased MDA and histamine content to 201.39% and 205.49%, respectively as compared to ginger treated group (Table I).

### Histopathological examinations

As shown in (Fig. 5a-5e), Histopathological examination of normal control rats' stomachs showed normal basic layers of the fundus can be distinguished (Fig. 5a). Rats subjected to pyloric ligation (ulcer control

rats) showed a severe disruption to the glandular epithelium and ulcer crater is clearly visible. Edema of the submucosal layer with lymphocytic infiltration was seen. Disrupted muscularis mucosa and inner circular layer of muscosa can also be noted (Fig. 5b).



**Fig. 5a-5e: Images from stomachs and Histopathological examination of each group.**

**Fig. 5a:** Image from stomach and a photomicrograph of the fundus of group 1 normal control group. **Fig. 5b:** Image from stomach and a photomicrograph of the fundus of group 2 - peptic ulcer control group (pyloric ligated). **Fig. 5c:** Image from stomach and a photomicrograph of the fundus of group 3 - famotidine (20 mg/kg, p.o.). **Fig. 5d:** Image from stomach and a photomicrograph of the fundus of group 4 - ginger (100 mg/kg, p.o.). **Fig. 5e:** Image from stomach and a photomicrograph of the fundus of group 5 - Marshmallow (100 mg/kg, p.o.). Where (white arrow) is lymphocytic infiltration or exfoliation of few cells, (black arrow) is the glandular mucosa, (★) is the submucosal layer, (MM) is the muscularis mucosa, (IC) is the inner circular layer of muscosa and (OL) is outer longitudinal layer.

Pretreatment with Famotidine showed nearly normal gastric mucosa with a small area of atrophied surface epithelium and exfoliation of few cells. The intact muscularis mucosa can be seen (Fig. 5c). Ginger pretreatment showed that the damage is limited to the superficial epithelium with detachment of few cells and intact muscularis mucosa. Edema of submucosa is noticed (Fig. 5d). Marshmallow pretreatment showed severe disruption to the glandular epithelium. Edema of the submucosal layer with inflammatory cells can notice and disrupted muscularis mucosa. Inner circular layer and outer longitudinal layer of muscosa are clearly observed (Fig. 5e).

## DISCUSSION

Phytochemical screening of test substances (marshmallow and ginger) was performed prior to work. The phytochemical screening of alcoholic extract of Ginger revealed the presence of carbohydrates, volatile oils, sterols and triterpenoids and alkaloids. [13, 39] The phytochemical screening of aqueous extract of Marshmallow revealed the presence of carbohydrates, volatile oils, tanins, flavonoids, and traces of saponins. [40]

Current investigation revealed that pyloric ligation for 4 hours caused significant ulceration in the glandular area of the rat stomach as seen in histopathological examination. This was associated by marked increase in ulcer number and ulcer index. [15] Pyloric ligation also showed increase in the gastric volume, titratable acidity and acid output. Similarly, pyloric ligation of rats for 4 hours resulted in accumulation of gastric secretory volume and increase in titratable acidity (reduction of pH of gastric juice) and gastric ulceration. [41] An increase in glycoprotein content in gastric juice after pyloric ligation was observed. [42] Pyloric ligation showed increase in peptic activity. Similar results have been reported increase in the pepsin activity in the gastric juice after pyloric ligation. [42-43] Pyloric ligation-induced ulcer was associated by oxidative stress as seen by increased MDA and decreased SOD and GSH.

Bafna and Balaraman (2011) also observed a decrease in the activity of SOD in pyloric ligation model. [44] Furthermore, pyloric ligation significantly increased histamine content. It has reported that gastric mucosal damage in the same model has been attributed to the decrease in mucosal defense due to starvation, increase in vagal discharge resulting in degranulation of mast cells and depletion of histamine in gastric tissue. [16] Gastric ulcer induced by pyloric ligation is believed to be due to stress induced increased in gastric hydrochloric acid secretion and/or stasis of acid. The volume of secretion is also an important factor in the formation of ulcer due to exposure of the unprotected lumen of the stomach to the accumulating acid. [15, 19] Pyloric ligation – induced gastric ulcers occurs because of an increase in acid-pepsin accumulation due to pyloric obstruction and subsequent mucosal digestion and breakdown of the gastric mucosal barrier. [41, 45]

Oxidative stress plays an important role in the pathogenesis of various diseases including gastric ulcer, with antioxidants being reported to play a significant role in the protection of gastric mucosa against various necrotic agents. [44] Reactive oxygen species are involved in the pathogenesis of pyloric ligation-induced gastric mucosal injury *in vivo*. [43] As compared to normal rats, pyloric ligation was found to increase lipid peroxidation and decrease SOD, CAT and GSH as compared to normal control groups, thus leading to oxidative stress. Preventive antioxidants, such as SOD and CAT enzymes are the first line of defense against reactive oxygen species. [46] GSH is a major low molecular weight scavenger of free radicals in the cytoplasm and an important inhibitor of free radical mediated lipid peroxidation. [44, 47] NO is an endogenous defensive factor for gastric cells and exhibits gastroprotective properties against different types of aggressive agents. [48] It is involved in the maintenance of mucosal integrity through the regulation of mucus and alkaline secretion, gastric motility and microcirculation. [49] NO is known to modulate acid levels, gastric mucus secretion, and blood flow in gastric tissues. NO has also been reported to prevent membrane lipid peroxidation. [50] NO can increase gastric blood flow and mucus secretion. [51]

Gastric secretion in this model has been shown to be mediated through histamine and is inhibited by H<sub>2</sub> antagonists. [52-53] Results of the present study revealed that famotidine protected animals from pyloric ligation-induced gastric ulceration as manifested by significantly reduced the ulcer number and ulcer index. It has been reported in aspirin and pyloric ligation induced gastric ulcer models that famotidine reduced the ulcer index thus showing the anti-secretory mechanism involved in the antiulcerogenic activity through H<sub>2</sub> receptors blockade. [54] Famotidine also significantly decreased titratable acidity and acid output after pyloric ligation. In addition famotidine produced a significant increase in the pH and decrease in the acidity of gastric secretions as well as significant decrease in glycoprotein content in gastric juice after pyloric ligation. Significant decrease in peptic activity was also observed. The antiulcer activity of famotidine was associated by reduction of oxidative stress as observed by reduction of MDA and marked increase in SOD and GSH. Other study reported that famotidine normalized all the oxidative stress parameters (GSH, TBARS and SOD) in ethanol model, aspirin model and pyloric ligation model. [16] Famotidine significantly increased NO content in pyloric ligation. Similar result has observed an increase in the level of NO in stomach tissue from ranitidine treated rats. [55] NO levels have been shown to be reduced in damaged stomach tissue. [56] Famotidine significantly decreased histamine content in pyloric ligation. vagally induced gastric secretion in this model has been shown to be mediated through histamine and is inhibited by H<sub>2</sub> antagonists.

[16] Therefore besides antagonizing H<sub>2</sub> receptors, Famotidine has also been shown to exhibit oxygen radical scavenging properties. [57]

Pretreatment with ginger showed antiulcer activity as seen by significant reduction of the ulcer number and ulcer index after pyloric ligation. These results further support that obtained by Al-Yahya *et al.* (1989). [58] Ginger significantly decreased glycoprotein content in gastric juice after pyloric ligation. Furthermore, Ginger extract significantly decreased peptic activity after pyloric ligation. In other study, Ethanol-induced depletion of gastric wall mucus has been significantly prevented by ginger. [13] The antiulcer activity of ginger was associated by reduction of oxidative stress as observed by significant decrease of MDA and increase in GSH and SOD after pyloric ligation. Ginger oil might act as a scavenger of oxygen radical and might be used as an antioxidant. [59] Likewise, recent study reported that *Zingiber officinale* significantly decreased MDA level in cerebral cortex, striatum, and hippocampus. [60] Similarly, *Zingiber officinale* increased the activity of SOD in cerebral cortex, hippocampus, and striatum. [60] One of the antiulcer activities of ginger could be due to the observed reduction of histamine release.

Marshmallow pretreatment showed antiulcer activity as observed by significant reduction of the ulcer number, ulcer index and peptic activity after pyloric ligation. Furthermore, marshmallow significantly reduced ulcer associated oxidative stress as manifested by significant decrease in MDA. Also histamine content was significantly decreased. Therefore the anti-ulcer effect of marshmallow could be attributed to reduction of oxidative stress and histamine release. The gastroprotective effect of marshmallow observed could be attributed to active compounds found in the extract such as flavonoids and mucilage polysaccharides. [12] *Althaea officinalis* L. has a mucus protection (cytoprotection effect) and an antioxidant effect. [61] According to the results of the present investigation, we can conclude that famotidine, ginger and marshmallow can protect against pyloric ligation induced ulcer.

## ACKNOWLEDGMENT

This work was supported by its authors.

## REFERENCES

1. Rao CV, Venkataramana K. A Pharmacological Review on Natural Antiulcer Agents. *J Global Trends Pharm Sci.* 2013; 4(3):1118-1131.
2. Taha AS, Hudson N, Hawkey CJ, Swannell AJ, Trye PN, Cottrell J, Mann SG, Simon TJ, Sturrock RD, Russell RI. Famotidine for the prevention of gastric and duodenal ulcers caused by nonsteroidal antiinflammatory drugs. *N Engl J Med.* 1996; 334(22):1435-1439
3. Ahirrao VK, Pawar RP. Simultaneous Quantification of Famotidine and Ibuprofen in Pharmaceutical Dosage by Using Validated Stability Indicating LC Method. *Res J Pharm Sci.* 2013; 2(4):1-9.
4. Qin Z, Chen C. Synergistic action of famotidine and chlorpheniramine on acetic acid-induced chronic gastric ulcer in rats. *World J Gastroenterol.* 2005; 11(45):7203-7207.
5. Sharma VN. Essentials of Pharmacology. Basic principles and general concepts. 3<sup>rd</sup> Edn, CBS Publishers & Distributors, New Delhi, Bangalore. 2007, pp. 673.
6. Kumar MR, Niyas MK, Mani TT, Rahiman OMF, Kumar SB. A review on medicinal plants for peptic ulcer. *Der Pharmacia Lettre.* 2011; 3(3):414-420.
7. Yamahara J, Huang Q. Gastrointestinal motility enhancing effect of ginger and its active constituents. *Chem Pharm Bull.* 1990 Feb; 38(2): 430-1.
8. Stewart JJ, Wood MJ, Wood CD, Mims ME. Effects of ginger on motion sickness susceptibility and gastric function. *Pharmacology* 1991; 42:111-120.
9. Banerjee S, Mullick HI, Banerjee J. *Zingiber officinale*: A Natural Gold. *Int J Pharm Bio Sci.* 2011; 2(1):283-294.
10. Deters A, Zippel J, Hellenbrand N, Pappai D, Possemeyer C, Hensel A. Aqueous extracts and polysaccharides from Marshmallow roots (*Althaea officinalis* L.): Cellular internalisation and stimulation of cell physiology of human epithelial cells *in vitro*. *J Ethnopharmacol.* 2010; 127:62-69.
11. Izzo AA, Di-Carlo G, Mascolo N, Autore G, Capasso F. Antiulcer effect of flavonoids, Role of endogenous PAF. *Phytother Res.* 1994; 29:87-93.
12. Hage-Sleiman R, Mroueh M, Daher CF. Pharmacological evaluation of aqueous extract of *Althaea officinalis* flower grown in Lebanon. *Pharm Biol.* 2011; 49(3):327-333.
13. Arun K, Ch VR, Vijayakumar M, Ayaz A, Naiyer S, Irfan KM. Anti-ulcerogenic and ulcer healing effects of *Zingiber officinale* (L.) On experimental ulcer models: possible mechanism for the inhibition of acid formation. *Int J Pharm Res.* 2010; 1(2):75-85.
14. Harborne JB. Phytochemical methods: A Guide to Modern Techniques of Plant Analysis. Chapman and Hall, London, 2007; ISBN: 81-8128-410-4, pp. 1-34.
15. Singh AP, Shukla V, Khare P. Effects of *plumeria obtusa* linn. in peptic ulcer induced by pylorus ligation & indomethacin. *J Pharm Sci Innov.* 2012; 26-32.
16. Bharti S, Wahane VD, Kumar VL. Protective effect of *Calotropis procera* latex extracts on experimentally induced gastric ulcers in rat. *J Ethnopharmacol.* 2010; 127:440-444.
17. Suleyman B, Halici Z, Odabasoglu F, Gocer F. The effect of Lacidipine on Indomethacin induced ulcer in rats. *Int J Pharmacol.* 2012; 8(2):115-121.
18. El-Abhar HS, Hammad LN, Abdel Gawad HS. Modulating effect of ginger extract on rats with ulcerative colitis. *J Ethnopharmacol.* 2008; 118:367-372.
19. Shay H, Komarow SA, Fels SS, Meranze D, Gruenstein M, Siplet H. A simple method for the uniform production of gastric ulceration in the rat. *Gastroenterology* 1945; 5:43-61.
20. Pendley CE, Fitzpatrick LR, Ewing RW, Molino BF, Martin GE. The gastrin/cholecystokinin-B receptor antagonist L-365,260 reduces basal acid secretion and prevents gastrointestinal damage induced by aspirin, ethanol and cysteamine in the rat. *J Pharmacol Exp Ther.* 1993; 265:1348-1354.
21. Khayyal MT, El-Ghazaly MA, Kenawy SA, Seif-EI-Nasr M, Mahran LG, Kafafi YA, Okpanyi SN. Antiulcerogenic effect of some gastro intestinally acting plant extracts and their combination. *Arzneimittel-forschung.* 2001; 51(7):545-553.
22. Cho CH, Olge CW. Cholinergic mediated gastric mast cells degranulation with subsequent histamine H<sub>1</sub> and H<sub>2</sub> receptors activation in stress ulceration in rats. *Eur J Pharmacol.* 1979; 55:23-33.
23. Hano J, Bugajski J, Danek L, Wantuch C. The effect of neuroleptics on the development of gastric ulcers in rats exposed to restraint cold stress. *Pol J Pharmacol Pharm.* 1976; 28:37-47.
24. Shay H, Sun DCH, Gruenstein M. A quantitative method for measuring spontaneous gastric secretion in the rat. *Gastroenterology* 1954; 26:906-913.
25. Grossman MI. Physiology for physician. A monthly Publication of the American Physiological Society 1963; 1:1-5.

26. Brodie DA, Hooke KF. The effect of vasoactive agents on stress-induced gastric hemorrhage in the rat. *Digestion* 1971; 4:193-204.
27. Jorgensen MB. A modified method for the determination of pepsinogen in urine (uropepsin). *Scand J Clin Invest.* 1954; 6:303-306.
28. Winzler RJ. Determination of serum glycoproteins. In: *Methods of Biochemical Analysis*, (ed: Glick, D.P.), Interscience Publishers, New York, NY, USA, 1955, pp. 279-311.
29. Demoly P, Lebel B, Messaad D, Sahla H, Rongier M, Daures JP, Godard P, Bousquet J. Predictive capacity of histamine release for the diagnosis of drug allergy. *Allergy* 1999; 54:500-506.
30. Wiley J. In: *Biochemical Pathways: An atlas of biochemistry and molecular biology* (G. Michael ed), New york, 1999, pp. 246.
31. Anderson ME. Glutathione in Free radicals: A Practical Approach (Punchard, N., Kelly, F.J., Ed.) Oxford University Press, New York, NY, 1996, pp. 213-226.
32. Halliwell B, Gutteridge JMC. *Free Radicals in Biology and Medicine*. 3<sup>rd</sup> edn. Oxford University Press, New York. 1999.
33. Li LF, Kao KC, Yang CT, Huang CC, Liu YY. Ethyl Pyruvate Reduces Ventilation-Induced Neutrophil Infiltration and Oxidative Stress. *Exp Biol Med.* 2012; 237(6):720-807.
34. Brindeiro CM, Lane PH, Carmines PK. Tempol Prevents Altered K<sup>+</sup> Channel Regulation of Afferent Arteriolar Tone in Diabetic Rat Kidney. *Hypertension* 2012; 59(3):657-664.
35. Kendrick KM, Guevara-Guzman R, Zorrilla J, Hinton MR, Broad KD, Mimmack M, Ohkura S. Formation of olfactory memories mediated by nitric oxide. *Nature* 1997; 388:670-674.
36. Connell BJ, Saleh MC, Khan BV, Rajagopal D, Saleh TM. UPEI-100, A Conjugate of Lipoic Acid and Apocynin, Mediates Neuroprotection in a Rat Model of Ischemia/Reperfusion. *Am J Physiol Regul Integr Comp Physiol.* 2012; 302(7):866-895.
37. Zhang Z, Zhang W, Jung DY, Ko HJ, Lee Y, Friedline RH, Lee E, Jun J, Ma Z, Kim F, Tsitsilianos N, Chapman K, Morrison A, Cooper MP, Miller BA, Kim JK. TRPM2 Ca<sup>2+</sup> Channel Regulates Energy Balance and Glucose Metabolism. *Am J Physiol Endocrinol Metab.* 2012; 302(7):807-816.
38. Drury RA, Wallington EA. *Carleton's Histological Techniques.*, 6<sup>th</sup> edition, Oxford University Press, London, 1980, pp. 183.
39. Ali BH, Blunden G, Tanira MO, Nemmar A. Some Phytochemical, Pharmacological and toxicological properties of ginger (*Zingiber officinale Roscoe*), a review of recent research, *Food Chem Toxicol.* 2008; 46:409-420.
40. Al-Snafi AE. The Pharmaceutical Importance of *Althaea Officinalis* and *Althaea Rosea*: A Review. *Int J Pharm Techno Res.* 2013; 5(3):1378-85.
41. Bhalke RD, Giri MA, Anarthe SJ, Pal SC. Antiulcer activity of the ethanol extract of leaves of *Sesbania grandiflora* (linn.). *Int J Pharm Pharm Sci.* 2010; 2(4):206-208.
42. Malash AM, Abdallah DM, Agha AM, Kenawy SA. Gastroprotective Efficacy of Coenzyme Q10 in Indomethacin-Induced Gastropathy: Other Potential Mechanisms. *Hindawi Publishing Corporation, Ulcers.* 2012; Article ID 957898: 7 pages.
43. Rastogi L, Patnaik GK, Dikshit M. Free radicals and antioxidant status following pylorus ligation induced gastric mucosal injury in rats. *Pharmacol Res.* 1998; 38(2):125-132.
44. Bafna PA, Balaraman R. Effect of activit, a herbomineral formulation, on experimentally-induced gastric lesions in rats. *J Appl Pharm Sci.* 2011; 1(10):134-139.
45. Sairam K, Rao CV, Dora Babu M, Vijay Kumar K, Agrawal VK, Goel RK. Antiulcerogenic effect of methanolic extract of *Emblca officinalis*: an experimentally study. *J Ethanopharmacol.* 2002; 82(1):1-9.
46. Suleyman H, Cadirci E, Albayrak A, Polat B, Halici Z, Koc F, Hacimuftuoglu A, Bayir Y. Comparative study on the gastroprotective potential of some antidepressants in indomethacin-induced ulcer in rats. *Chem Biol Interact.* 2009; 180:318-324.
47. Halliwell B. Antioxidant characterization: methodology and mechanism. *Biochem Pharmacol.* 1995; 49:1341-1348.
48. Samini M, Moezi L, Jabarizadeh N, Tavakolifar B, Shafaroodi H, Dehpour A. Evidences for involvement of nitric oxide in the gastroprotective effect of bromocriptine and cyclosporin A on water immersion stress-induced gastric lesions. *Pharmacol Res.* 2002; 46(6):519-523.
49. Tsukimi Y, Okabe S. Recent advances in gastrointestinal pathophysiology: role of heat shock proteins in mucosal defense and ulcer healing. *Biol Pharm Bull.* 2001; 24(1):1-9.
50. Abdallah IZA, Khattab HAH, Heeba GH. Gastroprotective Effect of *Cordia Myxa* L. Fruit Extract against Indomethacin-Induced Gastric Ulceration in Rats. *Life Sci J.* 2011; 8(3):433-445.
51. Nabavizadeh F, Alizadeh AM, Adeli S, Golestan M, Moloudian H, Kamalinejad M. Gastroprotective effects of *Stachys Lavandulifolia* extract on experimental gastric ulcer. *Afr J Pharm Pharmacol.* 2011; 5(2):155-159.
52. Salim AS. The role of vagal adrenergic activity in the mechanism of gastric acid secretion after pylorus-ligation in the rat. *J Pharm Pharmacol.* 1989; 41:566-568.
53. Andersson K, Chen D, Mattsson H, Sundler F, Håkanson R. Physiological significance of ECL-cell histamine. *Yale J Biol Med.* 1998; 71:183-193.
54. Ramachandran S, Poovi G, Dhanaraju MD. Evaluation of Gastric and Duodenal Antiulcer Activity of Famotidine Formulation in Experimental Animals. *J Pharmacol Toxicol.* 2011; 6(2):189-195.
55. Dursun H, Bilici M, Albayrak F, Ozturk C, Saglam MB, Alp HH, Suleyman H. Antiulcer activity of fluvoxamine in rats and its effect on oxidant and antioxidant parameters in stomach tissue. *BMC Gastroenterology* 2009; 9: 36.
56. Cadirci E, Suleyman H, Aksoy H, Halici Z, Ozgen U, Koc A, Ozturk N. Effects of *Onosma armeniacum* root extract on ethanol induced oxidative stress in stomach tissue of rats. *Chem Biol Interact.* 2007; 170:40-48.
57. Lapenna D, De Gioia S, Mezzetti A, Grossi L, Festi D, Marzio L, Cuccurullo F. H<sub>2</sub>-receptor antagonists are scavengers of oxygen radicals. *Eur J Clin Invest.* 1994; 24:476-481.
58. Al-Yahya MA, Rafatullah S, Mossa JS, Ageel AM, Parmar NS, Tariq M. Gastroprotective activity of ginger (zingiber officinale rosc) in albino rats. *Am J Chin Med.* 1989; 17(1-2):51-56.
59. Mishra RK, Kumar A, Kumar A. Review Article: Pharmacological Activity of *Zingiber Officinale*. *Int J Pharm Chem Sci.* 2012; 1(3):1073-1078.
60. Wattanathorn J, Jittiwat J, Tongun TH, Muchimapura S, Ingkaninan K. *Zingiber officinale* Mitigates Brain Damage and Improves Memory Impairment in Focal Cerebral Ischemic Rat. *Hindawi Publishing Corporation, Evidence-Based Complementary and Alternative Medicine*, 2011; Article ID 429505: 8 pages.
61. Farzaei MH, Rahimi R, Abbasabadi Z, Abdollahi M. An Evidence-based Review on Medicinal Plants used for the Treatment of Peptic Ulcer in Traditional Iranian Medicine. *Int J Pharmacol.* 2013; 9(2):108-124.

**Source of Support: Nil, Conflict of Interest: None declared.**