



Contents lists available at UGC-CARE

International Journal of Pharmaceutical Sciences and Drug Research

[ISSN: 0975-248X; CODEN (USA): IJPSPP]

Available online at www.ijpsdronline.com

Review Article

Androgenetic Alopecia: Update on Etiology, Pathophysiology, Diagnosis, and Treatment

Cherishma RP, Babiker BH Baraka*, Bhagya V Rao, Chetana S Karadi, Sneha V Gowda, Ramesh Kumar

Department of Pharmacology, KLE College of Pharmacy, Bangalore, Karnataka, India.

ARTICLE INFO

Article history:

Received: 08 February, 2024

Revised: 09 March, 2024

Accepted: 13 March, 2024

Published: 30 March, 2024

Keywords:

Androgenetic alopecia, Patterned hair loss, Non-scarring alopecia, Trichoscopy.

DOI:

10.25004/IJPSDR.2024.160220

ABSTRACT

Alopecia means loss of hair. Androgenetic alopecia (AGA), now called patterned hair loss (male pattern hair loss; MPHL, female pattern hair loss; FPHL), is caused by androgens in a predisposed individual. Factors like age, sex, genes, smoking, and alcohol modulate it. If untreated, this leads to psychological problems like stress, anxiety, depression and decrease self-confidence, which affect quality of life. A thorough clinical examination and a certain hormonal estimation could reveal levels of androgens, hyperandrogenism, adrenal hyperplasia polycystic ovarian syndrome (PCOS), and ovarian/adrenal tumors. A simple trichoscopy could show the typical picture of hair miniaturization commonly seen in this condition. Finally, a biopsy of the scalp could help in clinching conclusive diagnosis. Out of the many treatments at our disposal, non-pharmacologic methods like temporary camouflage techniques, synthetic hair wigs, hair-thickening fibers, hair weaving, pigmented powders are useful. Semi-permanent options like scalp micro-pigmentation (thorough tattooing) are useful to enhance appearances. The United States Food and Drug Administration (USFDA) approves pharmacologic treatments such as minoxidil and finasteride. The non-USFDA approved methods of treatments like various surgical procedures [hair transplantation]; follicular unit transplantation (FUT), follicular unit extraction (FUE), microneedling, light therapy, indigenous medicines, platelet-rich plasma (PRP)}, and various loco-regional hair care practices are in vogue. The outcome of this review is to offer the latest update and insights into the newer novel therapies in patterned hair loss. Also, the patients could enhance their knowledge about the condition, the benefits and prognosis of each treatment.

INTRODUCTION

Androgenetic alopecia (AGA), called pattern alopecia, is the most common disorder in both sexes. Alopecias can be broadly divided into scarring (cicatricial) and non-scarring (non-cicatricial). An estimation suggests that at least eighty percent of males and fifty percent of females by age 70 years, would develop this problem.^[1] In Indians, a prevalence of 58% in males aged (30–50 years) was found. Females have a higher propensity of developing FPHL after menopause because of compensatory adrenal overdrive.^[2] The incidence of the disease increases with age mostly being seen in Caucasians, Asians, Native Americans, African Americans, and Eskimos.^[1] Patterned hair loss (hair thinning) PHL is a colloquial

meaning of the terminology used because the hair is not lost but has thinned out under the shenanigans of androgens in a genetically predisposed individual.

In males, it presents as a predictable pattern hair loss that commonly affect the temples, vertex and midfrontal scalp.^[3] The main target areas in women typically affect the crown and temporal areas. However, the frontal hairline is usually spared.^[4] AGA has intense psychological impact on the patient regardless of their age and their stages of baldness. It has been recorded that early onset of PHL is a strong predictor of premature initiation of several diseases related to metabolic syndrome and heart (coronary heart disease). During the time of Shakespeare, the cause of PHL was not clearly understood, hence the only option for those with

***Corresponding Author:** Mr. Babiker BH Baraka

Address: Department of Pharmacology, KLE College of Pharmacy, Bangalore, Karnataka, India.

Email ✉: bashirbaraka118@gmail.com

Tel.: +91-7338560640

Relevant conflicts of interest/financial disclosures: The authors declare that the research was conducted in the absence of any commercial or financial relationships that could be construed as a potential conflict of interest.

© The Author(s) 2024. **Open Access.** This article is licensed under a Creative Commons Attribution 4.0 International License, which permits use, sharing, adaptation, distribution and reproduction in any medium or format, as long as you give appropriate credit to the original author(s) and the source, provide a link to the Creative Commons licence, and indicate if changes were made. The images or other third party material in this article are included in the article's Creative Commons licence, unless indicated otherwise in a credit line to the material. If material is not included in the article's Creative Commons licence and your intended use is not permitted by statutory regulation or exceeds the permitted use, you will need to obtain permission directly from the copyright holder. To view a copy of this licence, visit <https://creativecommons.org/licenses/by/4.0/>

alopecia was to live with it or use artificial hair like wigs, or extensions for cosmetic purposes. Now, we have a deeper and broad understanding of the pathophysiology, genetics and molecular basis of PHL, which has enabled an effective treatment modality. The significance of comprehending and addressing PHL is growing due to the emphasis on appearance and the desire to maintain a pleasing aesthetic.

Etiology

The male hormone- testosterone undergoes conversion to 5-dihydrotestosterone (DHT) primarily by 5-alpha-reductase enzyme after binding to respective residing androgen receptors.^[5] This 5-DHT is the culprit behind causing PHL. This DHT miniaturizes the hair follicles when the thick long coarse terminal hair becomes short soft, thin vellus hair which is perceived as “hair loss” rather than hair thinning. This in turn shortens anagen hair growth cycle. There are two main isoforms of the 5-alpha-reductase enzyme: Type I and II.^[6] Type I 5-alpha-reductase enzymes are predominately found on sebaceous glands, keratinocytes, and sweat glands.^[7] Type II 5-alpha-reductase enzymes are predominately located within the hair follicles’ outer root sheath and papilla.^[6] PHL is greatly influenced by type II 5-alpha-reductase enzyme. The prevailing theory suggests that PHL occurs due to an unusual responsiveness of hair follicles on the scalp to circulating androgens, possibly stemming from an elevation in the abundance of androgen receptors (AR). Androgens, especially 5-dihydrotestosterone (DHT) are pivotal in both the onset and advancement of PHL. The increased androgen receptor activation leads to a notable decrease in the duration of the anagen (growth phase), causing a gradual shrinking of hair follicles. The concentration total androgen receptors (AR) in the frontal hair follicles of females are 40% lesser when compared to those in males. The excessive reaction to androgens is known to be influenced by a variety of factors such as genetic predisposition, hormonal changes, environmental elements, and age. Genetic factors are key in determining the individual’s susceptibility to PHL, a specific gene variation can affect the sensitivity of the hair follicles to androgens. Hormonal changes like those who experienced during puberty, pregnancy, and menopause, can exacerbate the effect of androgens on the hair follicles, leading to increased hair shedding. Environmental factors like stress, and dietary habits can interreact with genetic and hormonal factors.

Pathophysiology

The growth cycle of hair can be categorized into 4 phases viz (growth) anagen phase, (involution) catagen phase, (resting) telogen phase, and (shedding) exogen phase.^[8] At any given time, approximately (80–90%) of hair follicles are in the active anagen growth phase, while about 5–10% are in the telogen resting phase. About 1% each are in catagen involuting and exogen-shedding phases. It

is during this anagen growth phase that large, long, thick, terminal coarse hair fibers are formed. Therefore, the extended span of the proliferative active phase dictates the length of the hair.^[9]

In PHL, the growth-anagen phase shortens with each successive cycle, whereas the telogen phase prolongs relatively. The elongation of the telogen phase is especially noticeable during the later part of telogen, coinciding with the shedding of hair (exogen shedding phase). This creates a reduced anagen: telogen ratio (1:1) normal ratio being 1:(4-7).^[10] This corresponds to the period of increased hair fall chiefly observed while washing or combing the hair. Balding results from this relatively prolonged latent telogen phase because of the rise in the vacant hair follicles. With each and every successive cycle of growth in hair, the length of the shaft of each hair strand decreases, resulting in a progressively shorter hair length.

The follicular pore seems empty as the anagen duration has briefly shortened, whereas the growing hair has not been able to achieve ample hair length to emerge on the skin’s surface.^[10] DHT causes this phenomenon of transforming terminal hair into vellus hair, resulting in gradual hair thinning.^[11]

The role of genetics

The proneness to PHL is mainly determined by gene factors, which contribute to approximately 80% of the tendency for hair loss. PHL is governed by a polygenic model, where there are different levels of gene expression, explaining the wide spectrum of clinical phenotype and initial differences affected by this condition.

In males, the genome-wide analyses have revealed significant strong signals with the AR gene, ectodysplasin A2 receptor (EDA2R) gene on Xq12 chromosome in PHL and in females, the identified genes are AR genes, estrogen receptor gene (ESR2), and the aromatase genes (CYP19). Other genes involved are SRD5A1 and SRD5A2 coded for 5-alpha-reductase enzymes, the aromatase gene, the insulin gene, and the nonrecombinant area of Y chromosome.^[7]

Steroid 5-alpha-reductase enzymes

Separated genes encode the 5-alpha-reductase enzyme. The SRD5A enzyme which is called steroid 5-alpha-reductase enzyme is a membrane-embedded protein with five members: SRD5A type one to three, (GSPN2) glycoprotein synaptic, and GSPN2-like. The SRD5A1 gene located on chromosome 5 encodes for type I 5-alpha-reductase, while the SRD5A2 gene which is situated on chromosome 2 encodes for type II 5-alpha-reductase.^[12] SRD5A1 transforms testosterone to its more potent form, DHT leading to BPH and SRD5A2 plays a role in PHL.^[13]

Insulin

The insulin gene is considered in PHL due to the potential association between PHL and polycystic ovary syndrome

(PCOS). Insulin plays a critical role in regulating the timing of the growth phases within the anagen and telogen cycles. A mutation occurring in the control region of the insulin gene that modifies the amount of insulin expression could potentially impact on the balance of anagen and telogen phases of hair growth.^[12]

Aromatase

The enzyme aromatase converts the CYP19 androgens, like testosterone can be transformed into estrogens. Mutation of this gene is rare, teenage girls experiencing puberty may develop virilization and hirsutism because of excess androgen levels.^[14] This implies that the aromatase gene is unlikely to be involved in predisposing individuals to PHL.^[12]

Estrogen receptor

Differences in the genes that encode the two types of estrogen receptors are ER-alpha, and ER-beta could contribute to the occurrence of PHL phenotype.^[12] ESR2, also known as estrogen receptor beta, is the primary receptor found within the hair follicles and it is believed to be among the main mediators of estrogen's corollary on hair follicles.

Studies on the estrogen receptor β gene indicate that hair follicles may become more receptive to estrogen rather than less so.

The increased responsiveness of hair follicles to estrogen contributes to hair thinning in women with this specific gene variant.^[7]

Diagnosis

Clinical features

Patient's history diagnoses PHL along with elucidation of clinical signs and symptoms. MPHL is diagnosed by using

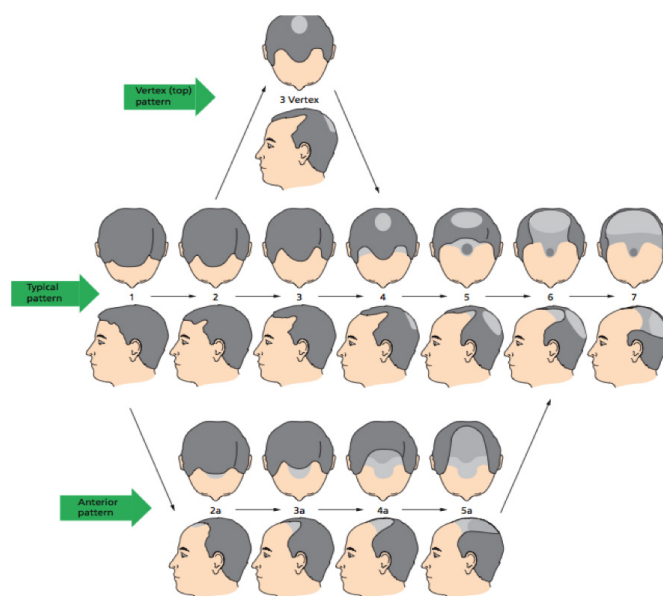


Fig. 1: Hamilton-Norwood scale of pattern hair loss in male

the Hamilton-Norwood scale (Fig. 1) whereas FPHL is diagnosed by following the Ludwig scale (Fig. 2).^[15] Patients could need investigations if they are suffering from severe acne, menstrual irregularities, menarche, menopause, infertility, signs of virilization.^[10]

Investigations

Blood and hormonal investigation includes:

- Dehydroepiandrosterone (DHEA)-sulphate and testosterone analysis: needed in women if virilization is evident.
- Total capacity of iron binding and transferrin saturation test to diagnose iron deficiency; to rule out chronic telogen effluvium.
- Thyrotropin (T3, T4) and thyrotropin stimulating hormone (TSH) levels, if thyroid disorder are suspected.^[16]

Laboratory investigations could be divided into invasive and non-invasive.

- Non-invasive methods are trichoscopy, hair pull test, tug test, card test, phototrichograms, and scalp digital photography.
- Invasive method is scalp biopsy.^[17]

Tug test

This test is performed to check hair fragility and hair shaft abnormalities. A tuft of hair is held between the fingers at

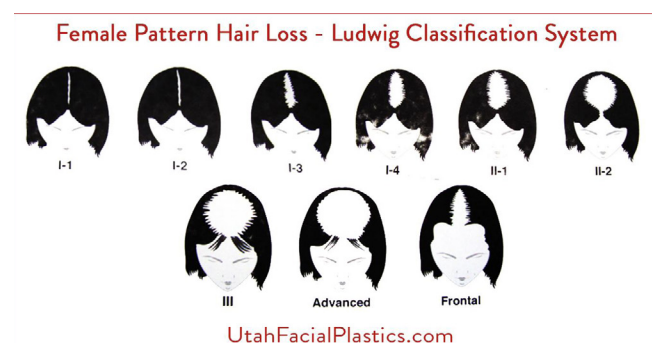

Fig. 2: Ludwig scale of pattern hair loss in female



Fig. 3: Tug test



the middle of the shaft of hair of one hand and with the other hand, forcefully pull the ends of the shaft of hair. A positive test implies breaks in the shaft of the hair^[18] (Fig. 3).

Hair pull test

This is an easy bedside technique to check the severity of hair shedding. A tuft of hair strands, around 40 to 60 are gripped using the index, thumb, and middle fingers which are pulled with a gentle yet firm touch. A positive test yields six and more hair, indicating underlying pathology of hair loss condition. Less than five or fewer hair indicate normal shedding. The test would be better conducted if patients are instructed to abstain from shampooing their hair for at least twenty-four hours^[8] (Fig. 4).

Scalp digital photography

It functions as a method of instrument-aided inspection that serves as a standardized measure to check diagnostic and prognostic features of certain alopecia. Scalp photography has been proven to decrease anxiety-related alopecia and enhance alignment between the clinical evaluation and patients' self-perception.^[19,20]

Trichoscopy

This aids in determining the hair loss of a specific type, especially in the initial stages for the early identification of a disease.^[11] Findings in trichoscopy are perifollicular erythema, mild scaling, and varied thickness of hair density. The advent of trichoscopy has negated the need to perform biopsy^[21] (Fig. 5).

Scalp biopsy

This could aid diagnosis when there is an uncertainty in the clinical picture or we suspect a coexisting scalp condition. A 2 mm punch biopsy is preferred to minimize scarring. The most common histopathologic findings in PHL are:

- Miniaturization of terminal hair (hair shaft diameter is ≤ 0.03 micrometer).
- Approximately 20% of telogen terminal hair is reduced to vellus hair in males expressed in a ratio of 1.9:1 and for females 1.5:1.
- Decreased overall density of hair per unit area.^[17]

Differential diagnosis

The differentials are telogen effluvium, postpartum loss of hair, diffuse cicatricial alopecia, and diffuse alopecia areata.

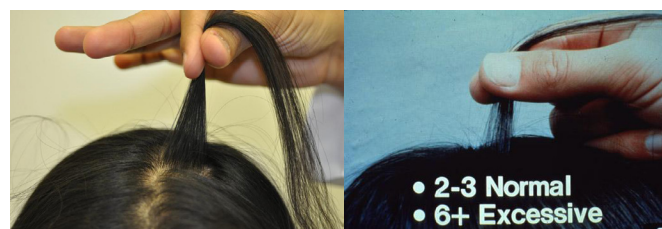

Fig. 4: Hair pull test

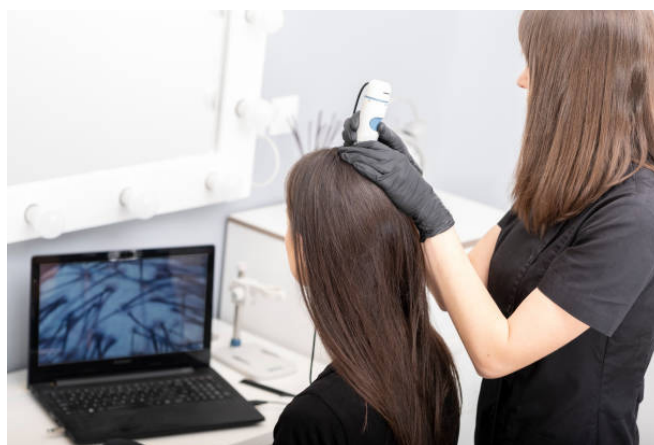

Fig. 5: Trichoscopy

Management

Conservative management

Adjustments to a hectic lifestyle, practicing regular/destressing mechanisms like yoga, meditation, exercise, and following loco-regional customs per haircare practices like applying and massaging hair oil go a long way in reducing and modulating hair elements and treatments.^[13]

Treatment

USFDA-approved treatments are oral minoxidil and finasteride. Other treatments like PRP, hair transplantation, light therapy, and ketoconazole are undergoing clinical trials for validation.

Minoxidil

The USFDA approved doses are two percent and five percent of Minoxidil. In males, 5% formulation is more effective 2% whereas in females both percentages are useful.^[11] The foam formulation provides promising results than the other formulation, such as shampoo, spray, and solutions, according to the recent studies.^{[13],[22]} Offlate 1-mg minoxidil tablet have gained entry into the market as studies have proven low dose systemic therapy.^[23] The sublingual minoxidil dose 0.45 mg daily was shown a promising result and had an acceptable safety profile in treating PHL.^[24]

Finasteride

It is a 5-alpha-reductase enzyme type II inhibitor. The USFDA has approved this medication to treat PHL and BPH.^[25] Later, sometime topical finasteride therapy evolved to circumvent the side effect profile of its systemic therapy. This went into disrepute as it was not as effective as systemic therapy. The drawback of finasteride is, it must be taken on a long term basis all while bearing its side effect profile the most concerning being adverse effects on females of reproductive age group.^[26] The efficacy of the therapy is seen after a lag period of one year and further improvement being observed up to ten years.^{[1],[27]}

Dutasteride

Dutasteride is a newer congener of finasteride and an inhibitor of both types I and II isozymes of 5- α -reductase. It has shown better results in MPHL than finasteride.^[28] Compared with finasteride, it has a hundred times greater potency in inhibiting 5- α -reductase type I and is three times more effective at inhibiting its type II isozyme.^{[1],[29]} Dutasteride appears to show better efficacy than finasteride for treating PHL.^[30]

Ketoconazole

The broadly used antifungal medication ketoconazole has both anti-androgenic and anti-inflammatory properties. In PHL, the ketoconazole shampoo has proven its effectiveness when particularly administered in conjunction with other treatments.^{[25],[31]}

Spirolactone

This is an off-label drug and more efficient anti-androgen treatment for FPHL.^[17] It remarkably works by inhibiting the androgen receptor and reducing ovarian production of androgens. The treatment needs to be continued for (6-9) months to evaluate its effectiveness. The side effect profile of headache, decreased libido, breast tenderness, and hyperkalaemia^[25] set a drawback for males with pattern hair loss.

Cyproterone acetate

Cyproterone acetate (CPA) is an anti-androgen drug that blocks androgen receptors (AR) and it lowers testosterone levels by inhibiting the release of luteinizing hormone (LH) and follicle-stimulating hormone release (FSH).^[25] Along with topical minoxidil, it has been helpful to treat females with PHL and additional signs of hyperandrogenism.^[11]

Clascoterone

A topical novel anti-androgen receptor inhibitor has revealed better results in recent trials.^[32] Experiments conducted *in-vitro* have illustrated that clascoterone is just as effective as finasteride. A preliminary industrial study demonstrates hair growth stimulation comparison with that of minoxidil.^[33]

Platelet-rich plasma (PRP)

Platelet-rich plasma with their growth factors, chemokines, and cytokines administered to the affected areas^[25] along with some boosters like calcium, collagen, and thrombin have been useful in cases of PHL.^[1] Hair transplantation procedures combined with PRP have shown mixed results, with some cases demonstrating considerable improvement in the density and revitalization of transplanted hair follicles.^[17,34]

Stem cell therapy

The stem cells hair follicle are mostly present in the hair bulge. The Wnt signaling pathway stimulation controls hair follicle development and differentiation.^[35] This is a

novel therapy where the trails have not been completed yet though there are no toxicity or adverse effects it is expensive and an invasive procedure.^[4]

Microneedling

Dermal roller is the instrument used for this minor procedure, which works by inciting the process of wound healing boosting hair follicle growth by enhancing collagen and elastin production. This procedure also helps as a conduit for transdermal administration of medications such as minoxidil PRP. This procedure is well tolerated with minimal undesirable effects.^{[25],[36]}

Hair transplantation

This procedure is minimally invasive where hair from donor site is grafted onto the bald area (recipient site). The concept is that the donor hair is resistant to androgen hormone effects.^[13] Hence post-operatively treatment with minoxidil and anti-androgens are needed. Though this is not USFDA approved, expensive patients have accepted this procedure worldwide.^[25,37] It has also exhibited promising results in many studies. The newer procedures like FUT and FUE have revolutionized hair transplantation down the years. Robot-assisted FUE has emerged, offering better benefits such as improved accuracy, efficiency in graft harvesting, reduced size of FUT, and enhanced precision in implantation at the recipient site.^[38,39]

Camouflage techniques

The temporary techniques are synthetic hair wigs, hair-thickening fibers, hair weaving techniques, and pigmented powders. Scalp-micro pigmentation, a semi-permanent technique which involves tattooing to create the impression of closely cropped hair follicles, can enhance one's visual appeal.^{[3],[13]}

Nutraceuticals and indigenous supplements

Plant-based oils

Rosemary oil extracted from (*Rosmarinus officinalis*) a medicinal plant enhances microcapillary perfusion, improves PGE2 production and helps in hair growth. Pumpkin seeds *via* 5-AR antagonism, increase the hair growth.^[40]

Hinoki gold oil (essential oil) is extracted from *Chamaecyparis obtuse* (hinoki cypress) and promotes hair growth through the increase in enzymes, cytokines, and growth factors and also increases the blood circulation supply nutrients to the hair follicles.^[41] Many more essential oils help in the hair development stimulation provided by enhancing micro-circulation within the follicles, decreasing scalp inflammation, or stimulating the secretion of growth factors.^[42]

Caffeine

Caffeine is a promising novel drug that increases cyclic adenosine monophosphate levels (cAMP) and cell



metabolism as they mimic phosphodiesterase inhibitors, helping reverse hair follicle miniaturization. Caffeine-based shampoo formulations showed similar efficacy.^[43] The impact of caffeine on follicles and shafts of the hair elongation studies performed in vitro have shown to differ based on dosage and gender. Studies by researchers have shown that in vivo penetration confirmed a promising result by reducing hair loss by utilizing caffeine-based topical formulation.^[44,45]

Ayurvedic supplements

Saw-palmetto extract derived from the American dwarf palm tree's berries which is a natural inhibitor of 5-alpha-reductase isozymes.^[1,46] Studies have shown that when it was administered to males, it increased hair growth.^[47] It is manufactured for external (topical) application and formulated into soft gels for oral intake.^[48]

CONCLUSION

Androgenetic alopecia (AGA) is among the most prevalent dermatological concerns for which the patient seeks treatment. Patterned hair loss has been attributed to the effects of androgens. Although limited treatments are currently available, ongoing research and understanding of its mechanisms and potential interventions offer hope for patients affected by this condition. However, the use of trichoscopy has helped in the early diagnosis of PHL. The USFDA-approved treatment minoxidil and finasteride have proved their efficacy. Novel treatments like microneedling, PRP, hair transplantation are being widely performed with patients accepting the promising results even though they are expensive and yet to get approval by the USFDA.

More double-blinded placebo-controlled randomized clinical trials are needed for these novel procedures to comment on their efficacy so that they could be widely utilized in patients suffering PHL.

REFERENCES

- Devjani S, Ezemma O, Kelley KJ, Stratton E, Senna M. Androgenetic Alopecia: Therapy Update. *Drugs*. 2023 Jun;83(8):701-715. doi: 10.1007/s40265-023-01880-x. Epub 2023 May 11. PMID: 37166619; PMCID: PMC10173235.
- Monil G, Snehal M, Veligandla KC, Rahul R, Gauri D, Bhavesh K, Snehal S. Epidemiology and Treatment Aspects of Hair Loss in India – A Cross-Sectional, Multicentre, Database Study (HAILO). *AJRDES* [Internet]. 2023 May 10 [cited 2024 Apr. 18];6(1):22-3. Available from: <https://journalajrdes.com/index.php/AJRDES/article/view/81>
- Asfour L, Cranwell W, Sinclair R. Male Androgenetic Alopecia. 2023 Jan 25. In: Feingold KR, Anawalt B, Blackman MR, Boyce A, Chrousos G, Corpas E, de Herder WW, Dhatariya K, Dungan K, Hofland J, Kalra S, Kaltsas G, Kapoor N, Koch C, Kopp P, Korbonits M, Kovacs CS, Kuohung W, Laferrère B, Levy M, McGee EA, McLachlan R, New M, Purnell J, Sahay R, Shah AS, Singer F, Sperling MA, Stratakis CA, Trencle DL, Wilson DP, editors. *Endotext* [Internet]. South Dartmouth (MA): MDText.com, Inc.; 2000-. PMID: 25905192.
- Kaiser M, Abdin R, Gaumont SI, Issa NT, Jimenez JJ. Treatment of Androgenetic Alopecia: Current Guidance and Unmet Needs. *Clin Cosmet Investig Dermatol*. 2023 May 31;16:1387-1406. doi: 10.2147/CCID.S385861. PMID: 37284568; PMCID: PMC10239632.
- Chen S, Xie X, Zhang G, Zhang Y. Comorbidities in Androgenetic Alopecia: A Comprehensive Review. *Dermatol Ther (Heidelb)*. 2022 Oct;12(10):2233-2247. doi: 10.1007/s13555-022-00799-7. Epub 2022 Sep 17. PMID: 36115913; PMCID: PMC9483356.
- Ho CH, Sood T, Zito PM. Androgenetic Alopecia. [Updated 2024 Jan 7]. In: StatPearls [Internet]. Treasure Island (FL): StatPearls Publishing; 2024 Jan-. Available from: <https://www.ncbi.nlm.nih.gov/books/NBK430924/>
- Dhurat RS, Daruwalla SB. Androgenetic alopecia: Update on etiology. *Dermatological Reviews* 2021; 1-7. <https://doi.org/10.1002/der.2.58>
- Thiedke CC. Alopecia in women. *Am Fam Physician*. 2003 Mar 1;67(5):1007-14. PMID: 12643360.
- Natarelli N, Gahoonia N, Sivamani RK. Integrative and Mechanistic Approach to the Hair Growth Cycle and Hair Loss. *J Clin Med*. 2023 Jan 23;12(3):893. doi: 10.3390/jcm12030893. PMID: 36769541; PMCID: PMC9917549.
- DA Burns, SM Breathnach, NH Cox and CEM Griffiths. *Rook's Textbook of Dermatology*. 8th edition. West Sussex. Wiley Blackwell Publishing; 2010
- Fabbrocini G, Cantelli M, Masarà A, Annunziata MC, Marasca C, Cacciapuoti S. Female pattern hair loss: A clinical, pathophysiologic, and therapeutic review. *Int J Womens Dermatol*. 2018 Jun 19;4(4):203-211. doi: 10.1016/j.ijwd.2018.05.001. PMID: 30627618; PMCID: PMC6322157.
- Ellis JA, Harrap SB. The genetics of androgenetic alopecia. *Clin Dermatol*. 2001 Mar-Apr;19(2):149-54. doi: 10.1016/s0738-081x(00)00125-5. PMID: 11397593.
- Ntshingila S, Oputu O, Arowolo AT, Khumalo NP. Androgenetic alopecia: An update. *JAAD Int*. 2023 Jul 22;13:150-158. doi: 10.1016/j.jdin.2023.07.005. PMID: 37823040; PMCID: PMC10562178.
- Trüeb RM. Molecular mechanisms of androgenetic alopecia. *Exp Gerontol*. 2002 Aug-Sep;37(8-9):981-90. doi: 10.1016/s0531-5565(02)00093-1. PMID: 12213548.
- Martinez-Jacobo L, Villarreal-Villarreal CD, Ortiz-López R, Ocampo-Candiani J, Rojas-Martínez A. Genetic and molecular aspects of androgenetic alopecia. *Indian J Dermatol Venereol Leprol*. 2018 May-Jun;84(3):263-268. doi: 10.4103/ijdv.IJDVL_262_17. PMID: 29595184.
- Feinstein RP, Butler DF, Chan EF, Khardori R, Sperling L. Androgenetic Alopecia. *Medscape Updated Mar 25, 2024*.
- Tamashunas NL, Bergfeld WF. Male and female pattern hair loss: Treatable and worth treating. *Cleve Clin J Med*. 2021 Mar 1;88(3):173-182. doi: 10.3949/ccjm.88a.20014. PMID: 33648970.
- Singh S, Muthuvel K. Practical Approach to Hair Loss Diagnosis. *Indian J Plast Surg*. 2021 Dec 27;54(4):399-403. doi: 10.1055/s-0041-1739240. PMID: 34984076; PMCID: PMC8719967.
- Pathoulas JT, Flanagan KE, Walker CJ, Wiss IMP, Azimi E, Senna MM. Evaluation of standardized scalp photography on patient perception of hair loss severity, anxiety, and treatment. *J Am Acad Dermatol*. 2021 Dec;85(6):1640-1641. doi: 10.1016/j.jaad.2020.12.059. Epub 2021 Jan 7. PMID: 33421478.
- Serrano-Falcón C, Fernández-Pugnaire MA, Serrano-Ortega S. Hair and scalp evaluation: the trichogram. *Actas Dermosifiliogr*. 2013 Dec;104(10):867-76. English, Spanish. doi: 10.1016/j.ad.2013.03.004. Epub 2013 Jul 18. PMID: 23871642.
- Kasumagic-Halilovic E. Trichoscopic Findings in Androgenetic Alopecia. *Med Arch*. 2021 Apr;75(2):109-111. doi: 10.5455/medarch.2021.75.109-111. PMID: 34219869; PMCID: PMC8228579.
- Pekmezci E, Turkoğlu M, Gökalep H, Kutlubay Z. Minoxidil Downregulates Interleukin-1 Alpha Gene Expression in HaCaT Cells. *Int J Trichology*. 2018 May-Jun;10(3):108-112. doi: 10.4103/ijt.ijt_18_17. PMID: 30034189; PMCID: PMC6029000.
- Ramos PM, Sinclair RD, Kasprzak M, Miot HA. Minoxidil 1 mg oral versus minoxidil 5% topical solution for the treatment of female-pattern hair loss: A randomized clinical trial. *J Am Acad Dermatol*. 2020 Jan;82(1):252-253. doi: 10.1016/j.jaad.2019.08.060. Epub 2019 Aug 29. PMID: 31473295.
- Sinclair R, Trindade de Carvalho L, Ferial Ismail F, Meah N.

- Treatment of male and female pattern hair loss with sublingual minoxidil: a retrospective case-series of 64 patients. *J Eur Acad Dermatol Venereol.* 2020 Dec;34(12):e795-e796. doi: 10.1111/jdv.16616. Epub 2020 Jul 28. PMID: 32386429.
25. Starace M, Orlando G, Alessandrini A, Piraccini BM. Female Androgenetic Alopecia: An Update on Diagnosis and Management. *Am J Clin Dermatol.* 2020 Feb;21(1):69-84. doi: 10.1007/s40257-019-00479-x. PMID: 31677111.
 26. Dhurat R, Sharma A, Rudnicka L, Kroumpouzou G, Kassir M, Galadari H, Wollina U, Lotti T, Golubovic M, Binic I, Grabbe S, Goldust M. 5-Alpha reductase inhibitors in androgenetic alopecia: Shifting paradigms, current concepts, comparative efficacy, and safety. *Dermatol Ther.* 2020 May;33(3):e13379. doi: 10.1111/dth.13379. Epub 2020 Apr 24. PMID: 32279398.
 27. Rossi A, Cantisani C, Scarnò M, Trucchia A, Fortuna MC, Calvieri S. Finasteride, 1 mg daily administration on male androgenetic alopecia in different age groups: 10-year follow-up. *Dermatol Ther.* 2011 Jul-Aug;24(4):455-61. doi: 10.1111/j.1529-8019.2011.01441.x. PMID: 21910805.
 28. Arif T, Dorjay K, Adil M, Sami M. Dutasteride in Androgenetic Alopecia: An Update. *Curr Clin Pharmacol.* 2017;12(1):31-35. doi: 10.2174/1574884712666170310111125. PMID: 28294070.
 29. Clark RV, Hermann DJ, Cunningham GR, Wilson TH, Morrill BB, Hobbs S. Marked suppression of dihydrotestosterone in men with benign prostatic hyperplasia by dutasteride, a dual 5alpha-reductase inhibitor. *J Clin Endocrinol Metab.* 2004 May;89(5):2179-84. doi: 10.1210/jc.2003-030330. PMID: 15126539.
 30. Zhou Z, Song S, Gao Z, Wu J, Ma J, Cui Y. The efficacy and safety of dutasteride compared with finasteride in treating men with androgenetic alopecia: a systematic review and meta-analysis. *Clin Interv Aging.* 2019 Feb 20;14:399-406. doi: 10.2147/CIA.S192435. PMID: 30863034; PMCID: PMC6388756.
 31. Inui S, Itami S. Reversal of androgenetic alopecia by topical ketoconazole: relevance of anti-androgenic activity. *J Dermatol Sci.* 2007 Jan;45(1):66-8. doi: 10.1016/j.jdermsci.2006.08.011. Epub 2006 Sep 25. PMID: 16997533.
 32. Hebert A, Thiboutot D, Stein Gold L, Cartwright M, Gerloni M, Frangos A, Mazzetti A. Efficacy and Safety of Topical Clascoterone Cream, 1%, for Treatment in Patients With Facial Acne: Two Phase 3 Randomized Clinical Trials. *JAMA Dermatol.* 2020 Jun 1;156(6):621-630. doi: 10.1001/jamadermatol.2020.0465. PMID: 32320027; PMCID: PMC7177662.
 33. Sun HY, Sebaratnam DF. Clascoterone as a novel treatment for androgenetic alopecia. *Clin Exp Dermatol.* 2020 Oct;45(7):913-914. doi: 10.1111/ced.14292. Epub 2020 Jun 23. PMID: 32421862.
 34. Cervantes J, Perper M, Wong LL, Eber AE, Villasante Fricke AC, Wikramanayake TC, Jimenez JJ. Effectiveness of Platelet-Rich Plasma for Androgenetic Alopecia: A Review of the Literature. *Skin Appendage Disord.* 2018 Jan;4(1):1-11. doi: 10.1159/000477671. Epub 2017 Jun 24. PMID: 29457005; PMCID: PMC5806173.
 35. Gentile P, Garcovich S. Advances in Regenerative Stem Cell Therapy in Androgenic Alopecia and Hair Loss: Wnt pathway, Growth-Factor, and Mesenchymal Stem Cell Signaling Impact Analysis on Cell Growth and Hair Follicle Development. *Cells.* 2019 May 16;8(5):466. doi: 10.3390/cells8050466. PMID: 31100937; PMCID: PMC6562814.
 36. Starace M, Alessandrini A, Brandi N, Piraccini BM. Preliminary results of the use of scalp microneedling in different types of alopecia. *J Cosmet Dermatol.* 2020 Mar;19(3):646-650. doi: 10.1111/jocd.13061. Epub 2019 Jun 29. PMID: 31254437.
 37. Kanti V, Messenger A, Dobos G, Reygagne P, Finner A, Blumeyer A, Trakatelli M, Tosti A, Del Marmol V, Piraccini BM, Nast A, Blume-Peytavi U. Evidence-based (S3) guideline for the treatment of androgenetic alopecia in women and in men - short version. *J Eur Acad Dermatol Venereol.* 2018 Jan;32(1):11-22. doi: 10.1111/jdv.14624. Epub 2017 Nov 27. PMID: 29178529.
 38. Zito PM, Raggio BS. Hair Transplantation. 2023 Feb 14. In: StatPearls [Internet]. Treasure Island (FL): StatPearls Publishing; 2024 Jan-. PMID: 31613520.
 39. Avram MR, Watkins SA. Robotic follicular unit extraction in hair transplantation. *Dermatol Surg.* 2014 Dec;40(12):1319-27. doi: 10.1097/DSS.0000000000000191. PMID: 25418806.
 40. Nestor MS, Ablon G, Gade A, Han H, Fischer DL. Treatment options for androgenetic alopecia: Efficacy, side effects, compliance, financial considerations, and ethics. *J Cosmet Dermatol.* 2021 Dec;20(12):3759-3781. doi: 10.1111/jocd.14537. Epub 2021 Nov 6. PMID: 34741573; PMCID: PMC9298335.
 41. Lee GS, Hong EJ, Gwak KS, Park MJ, Choi KC, Choi IG, Jang JW, Jeung EB. The essential oils of *Chamaecyparis obtusa* promote hair growth through the induction of vascular endothelial growth factor gene. *Fitoterapia.* 2010 Jan;81(1):17-24. doi: 10.1016/j.fitote.2009.06.016. Epub 2009 Jul 2. PMID: 19576968.
 42. Viveiros EP, Carvalho ALM, Lopes TB de C, Ramos IF da S, Alves PNN. Essential oils in androgenetic alopecia management: An integrative review. *Editora [Internet].* 2023 Apr. 10 [cited 2024 Apr. 18]; Available from: <https://sevenpublicacoes.com.br/index.php/editora/article/view/848>
 43. Fischer TW, Herczeg-Lisztes E, Funk W, Zillikens D, Bíró T, Paus R. Differential effects of caffeine on hair shaft elongation, matrix and outer root sheath keratinocyte proliferation, and transforming growth factor- β 2/insulin-like growth factor-1-mediated regulation of the hair cycle in male and female human hair follicles in vitro. *Br J Dermatol.* 2014 Nov;171(5):1031-43. doi: 10.1111/bjd.13114. Epub 2014 Oct 30. PMID: 24836650.
 44. Völker JM, Koch N, Becker M, Klenk A. Caffeine and Its Pharmacological Benefits in the Management of Androgenetic Alopecia: A Review. *Skin Pharmacol Physiol.* 2020;33(3):93-109. doi: 10.1159/000508228. Epub 2020 Jun 29. PMID: 32599587.
 45. Dhurat R, Chitallia J, May TW, Jayaraman AM, Madhukara J, Anandan S, Vaidya P, Klenk A. An Open-Label Randomized Multicenter Study Assessing the Noninferiority of a Caffeine-Based Topical Liquid 0.2% versus Minoxidil 5% Solution in Male Androgenetic Alopecia. *Skin Pharmacol Physiol.* 2017;30(6):298-305. doi: 10.1159/000481141. Epub 2017 Oct 21. PMID: 29055953; PMCID: PMC5804833.
 46. Ring C, Heitmiller K, Correia E, Gabriel Z, Saedi N. Nutraceuticals for Androgenetic Alopecia. *J Clin Aesthet Dermatol.* 2022 Mar;15(3):26-29. PMID: 35342503; PMCID: PMC8944288.
 47. Prager N, Bickett K, French N, Marcovici G. A randomized, double-blind, placebo-controlled trial to determine the effectiveness of botanically derived inhibitors of 5-alpha-reductase in the treatment of androgenetic alopecia. *J Altern Complement Med.* 2002 Apr;8(2):143-52. doi: 10.1089/acm.2002.8.143. Erratum in: *J Altern Complement Med.* 2006 Mar;12(2):199. PMID: 12006122.
 48. Gupta AK, Talukder M, Bamimore MA. Natural products for male androgenetic alopecia. *Dermatol Ther.* 2022 Apr;35(4):e15323. doi: 10.1111/dth.15323. Epub 2022 Jan 27. PMID: 35044013.

HOW TO CITE THIS ARTICLE: Cherishma RP, Baraka BBH, Rao BV, Karadi CS, Gowda SV, Kumar R. Androgenetic Alopecia: Update on Etiology, Pathophysiology, Diagnosis, and Treatment. *Int. J. Pharm. Sci. Drug Res.* 2024;16(2):286-292. DOI: 10.25004/IJPSDR.2024.160220

